

Review Article

Taiwan J Ophthalmol 2019;9:160-165

Access this article online

Quick Response Code:



Website:
www.e-tjo.org

DOI:
10.4103/tjo.54_19

Lamellar sclerokeratoplasty: Review of the literature and description of a special technique using fibrin glue and a giant hydrophilic contact lens

Eduardo Arenas¹, Alexandra Mieth²

Abstract:

Lamellar sclerokeratoplasty is a surgical procedure described since 1979 by Lim in China and reported by different surgeons in the world. Our purpose is to report a modified technique in which not only the whole cornea with a scleral rim is utilized, but the importance of including the whole Schlemm's canal area is also insisted; therefore, a new aqueous humor drainage pathway can be restored. The technique is designed for cases in which not only the whole cornea is decompensated, but also have untreatable glaucoma. This procedure replaces the entire anterior segment with a clear donor cornea including the limbus and part of the trabecular meshwork. We present the results of visual acuity by the logMAR scale of 55 cases from 110 patients receiving this surgical technique. The results describe 39 cases that had visual improvement after more than 1 year of follow-up and 16 cases that did not improve in their visual acuity. Large-diameter sclerokeratoplasty is an alternative and therapeutic option to eliminate the entire corneal pathology, while obtaining structural and even optical results with a lower immunological reaction. It can be considered an option in cases that are not suitable for standard grafting procedures.

Keywords:

Corneal transplant, penetrating keratoplasty, sclerokeratoplasty

Introduction

The idea of performing corneal grafting containing the scleral edge was first reported by Malbran in 1965 who performed lamellar keratoplasty using a graft containing the scleral rim.^[1] The term sclerokeratoplasty was introduced by Li in China in 1979 who reported some cases;^[2] later, Hallermann also published the result for the management of keratoglobus,^[3] and Taylor and Stern in 1980 published results for corneal reconstruction.^[4] The use of a total sclero-corneal donor of 18 mm in diameter was proposed by Girard^[5] and Ruiz and Saldarriaga^[6] in 1982, and 2 years later, Barraquer published a paper reporting 25 cases with some visual recovery.^[7]

In 1988, Bailiwick from Dresden mentioned the realization of a tectonic sclerokeratoplasty for the treatment of severe Sjogren disease,^[8] Mendez and Daza in 1991 used the technique for the treatment of a corneo-scleral dermoid^[9] and in the same year, Nikolić from Serbia published all the surgical options for the management of destructive corneal diseases including sclerokeratoplasty.^[10] In 1992, Cobo *et al.* described a technique introducing the use of sclero-lamellar penetrating keratoplasty in five cases with good preservation of the intraocular pressure (IOP) up to 90 months.^[11] In 1999, Anita Panda from India published the results of 166 cases of lamellar sclerokeratoplasty, reporting good visual recovery in 30% of the cases, with good cosmetic results in the majority of cases.^[12]

This is an open access journal, and articles are distributed under the terms of the Creative Commons Attribution-NonCommercial-ShareAlike 4.0 License, which allows others to remix, tweak, and build upon the work non-commercially, as long as appropriate credit is given and the new creations are licensed under the identical terms.

For reprints contact: reprints@medknow.com

How to cite this article: Arenas E, Mieth A. Lamellar sclerokeratoplasty: Review of the literature and description of a special technique using fibrin glue and a giant hydrophilic contact lens. Taiwan J Ophthalmol 2019;9:160-5.

¹Profesor, El Bosque University and National University, Bogota, Colombia,
²Director, ASOCORNEA, Colombia

Address for correspondence:

Prof. Eduardo Arenas,
Profesor, El Bosque University and National University, Bogota, Colombia.
E-mail: earenascale@gmail.com

Submission: 02-01-2019

Accepted: 12-06-2019

Previously, we had introduced the use of fibrin glue instead of sutures for lamellar sclerokeratoplasty in 2003 and published the technique in 2006,^[13] ever since we have done the procedure in 110 cases. Later, Kumar and Panda have also used fibrin glue for lamellar sclerokeratoplasty.^[14] Hereby, we present the details of the technique to be used in cases with total opaque corneas after more than one failed corneal transplantation, and as a last hope to recover some vision, a better cosmesis, and anterior-segment integrity.

Technique Description

The purpose of this new technique is to offer a new way of treatment for those eyes with complete opaque cornea after failed previous corneal grafts, or severely damaged anterior-segment area, and with untreatable glaucoma, in which a new, regular corneal transplantation will be unlikely to succeed. The procedure replaces the entire anterior segment with a clear donor cornea including the limbus and part of the trabecular meshwork so that a new aqueous humor drainage pathway can be restored, which permits a better function of the newly transplanted cornea. The replacement of sutures with a vital glue diminishes the surgical trauma and the immune response from the host caused by the sutures, and the inclusion of a lamellar scleral flap delays the limbal immunological reaction.

The procedure should be performed only under general anesthesia to avoid any risk of expulsive hemorrhage or collapse of the posterior segment while removing the whole cornea, limiting the technique only to the anterior segment of the eye.

Description of the Surgical Procedure

1. Before placing the patient under general anesthesia, the procedure is first started on the donor tissue, which should be a complete eyeball, with removal of all the conjunctival remnants attached to the limbus [Figure 1a and b]
2. To facilitate manipulation of the eye globe and dissection of the sclera, the donor should be inflated through the optic nerve by injecting balance salt solution or Ringer's solution with a fine 30G needle attached to a 2.5-mL syringe to elevate the IOP [Figure 1c]
3. The scleral zone is imprinted with a special scleral marker or using a vital dye such as Lissamine Green, where the area of the lamellar dissection would be performed. There are three choices in diameter, namely, 16.5 mm, 17 mm, and 18 mm [Figure 1d]
4. Four peripheral deep intrastromal injections of depot corticosteroid are introduced into the four quadrants of the donor cornea [Figure 1e]

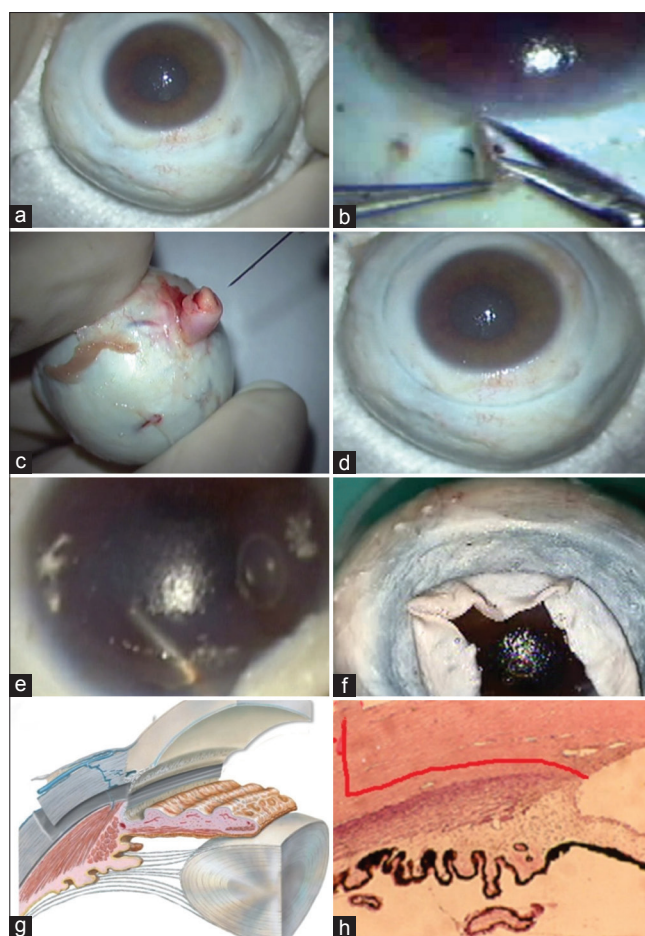


Figure 1: Donor preparation in lamellar sclerokeratoplasty. (a) Complete fresh eye globe donor. (b) Peeling of any residual limbal conjunctiva. (c) Injection of saline fluid throughout the donor optic nerve. (d) Scleral dissection zone imprinted with a special mold. (e) Intrastromal injection of depot cortisone in the four quadrants. (f) Lamellar dissection of the donor sclera around 360°. (g and h) Resection of the sclero-corneal donor including trabecular zone (red solid line in h: plane of dissection)

5. With a crescent knife, circular lamellar dissection of the sclera is started slowly from the periphery toward the center, until reaching the limbal area [Figure 1f]
6. The anterior chamber (AC) of the donor eye is punctured with a 15° keratome knife, and filled with viscoelastic material
7. Resection of the donor corneo-scleral junction is started with a Castroviejo corneal scissors. Carefully include the trabecular area and maintain a well-formed AC [Figure 1g and h]. After resection, the harvested corneo-scleral tissue is still temporarily placed over the donor globe, which is filled with viscoelastic material in the AC so as to protect the corneal endothelium
8. With the patient under general anesthesia, the second part of the surgery is started, utilizing a spring-controlled blepharostat
9. Two limbal 7-0 vicryl fixation sutures are placed at 12 and 6 o'clock hours, and attached to a mosquito forceps [Figure 2a]

10. The conjunctiva of the donor is dissected 360° around the limbus in order to uncover the episclera, and throughout two long diagonal incisions, each end is fixed with two 7-0 vicryl sutures, in the right eye at 10 and 4 o'clock hours with two mosquito forceps, and if it is the left eye, at 2 and 8 o'clock hours. It is not recommended to use cautery to avoid excessive trauma over the scleral surface. We recommend using small pieces of Weck-Cel® sponge, which are placed over the bleeding site for 40 s before removing them. The Weck-Cel piece is preferably rinsed with xylocaine–epinephrine and removed in a sliced way in order to keep the cloth intact^[15] [Figure 2b]
11. Once the sclera is completely uncovered, two specially designed stainless steel ring arcs are fixed to

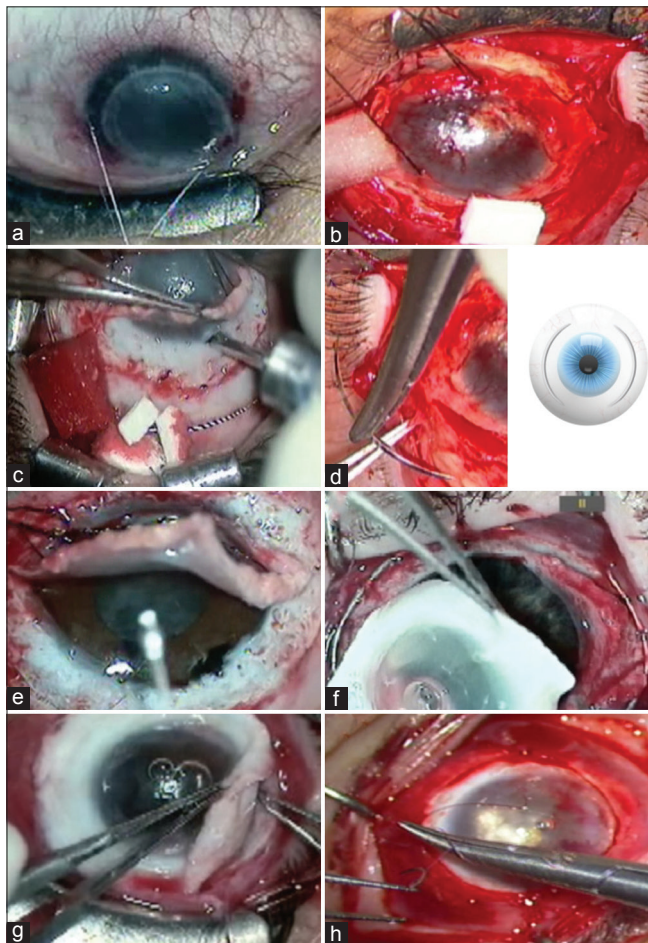


Figure 2: Recipient preparation and surgical procedures in lamellar sclerokeratoplasty. (a) Two tracking vicryl 7-0 sutures opposed to the limbal area. (b) Dissection of the lamellar scleral flap with a crescent dissector at approximately 300 μ deep. (c) Aspiration of fluid vitreous with an 18-mm diameter cannula. (d) Placement of two special Flieringa arcs around the recipient. (e) Injection of viscoelastic material into the anterior chamber to facilitate excision of the cornea, separation of anterior or posterior synechias, and extracapsular cataract extraction (if exists). (f) The sclero-corneal button is placed gently over the recipient previously filled with the viscoelastic material in the anterior chamber. (g) Fibrin glue is applied under the scleral flap with a curved forceps at four equidistant points. (h) The two previous conjunctival flaps are closed with the vicryl suture close to the new limbal area

- the sclera with vicryl sutures in order to maintain the recipient's eye globe in a spherical shape, avoiding a sudden decompression once the whole cornea with the lamellar scleral rim is removed [Figure 2c and d]
12. Using a crescent knife, dissection of the lamellar scleral flap usually begins at 12 o'clock hour, and try to keep the same level around 360°. Bleeding is stopped with Weck-Cel pieces. Avoid cautery as best as possible [Figure 2e]
13. With a crescent knife, a careful dissection 2 mm away from the limbus is made slowly, starting superiorly at the sclera around the whole cornea, creating a thin lamellar scleral flap
14. The next step is very important to avoid expulsive hemorrhage: dissect slowly in the right superior side of the recipient until reaching the iris root in order to perform a minimal peripheral iridectomy. This will permit the introduction of a special 18-mm diameter cannula to the central vitreous cavity, and aspirate approximately 1 mL of the vitreous fluid [Figure 2c and d]
15. To maintain normal IOP, sodium hyaluronate is introduced into the AC, and a slow resection of the recipient's corneo-sclera is initiated, trying to separate the possible anterior synechias at the same time with a fine round-edged spatula
16. Bleeding into the AC should be avoided with the use of small Weck-Cel pieces until the new AC has been formed [Figure 2e]
17. Once the resection of the recipient's cornea reaches 180°, the AC should be restored by trying to liberate the synechias and normalize its boundary. In some cases when the lens is opaque, it should be removed in an extracapsular fashion with an intraocular lens (IOL) implantation
18. Once the scleral borders are completely dry and are without blood, a viscoelastic material (sodium hyaluronate) is placed over the iris surface, the donor sclero-cornea is placed and adjusted, and three 7-0 vicryl sutures are placed [Figure 2f]
19. The fibrin glue is now prepared, and is placed with a curved jeweler's forceps under the scleral flap without moving the graft, which is allowed to remain still for 3 min [Figure 2g]
20. The two conjunctival flaps previously prepared with the mosquito forceps and 7-0 vicryl sutures are closed and anchored to the limbus of the donor's sclero-cornea [Figure 2h]
21. A giant 22-mm soft contact lens (Surgilens®) is placed over the recipient's eye globe^[16] [Figure 3a]
22. The surgery is finished by placing two temporary eyelid sutures (temporary tarsorrhaphy) with 8-0 polypropylene cardiovascular suture, to partially close the eyelids [Figure 3b and c]
23. The surgery is then completed with the eye covered with a bandage patch and an eye protection shield.

Postoperative Medications

Only systemic analgesics and antibiotics are prescribed for the next 24 h. The patient is sent home, instructed not to rub the eye and remain still.

Postoperative Follow-up Schedule

The next day, the eye is uncovered and carefully cleaned with a cotton swab. Care should be taken not to push the eye globe. With a jeweler's forceps, the eyelashes are cleaned to permit some partial blinking. A few drops of lubricants and antibiotic solutions are given to avoid the accumulation of deposits. The eye remains covered with a bandage for the next 5 days. Corticosteroid-antibiotic eye drops are applied three times a day in the inner cantus. Although short-term systemic immunosuppressant can be given to decrease post-op inflammation, the patients usually do not require long-term systemic immunosuppression.

After the 1st week, the eye patch is removed, leaving only the eye protection shield day and night for at least 2 weeks. An eye examination is done every week for the 1st month, and then monthly for 3 months, when the temporary tarsorrhaphy sutures and the soft contact giant lens are removed [Figure 3c].

Results

This technique was performed on 110 patients, but in this article, we included only 55 cases in whom we could complete follow-up for more than 1 year because others were followed up by institutional allies. The causes for performing lamellar sclerokeratoplasty in our list were as follows: 41 cases with failed penetrating keratoplasty,

7 cases after severe damage to the cornea and anterior segment, 5 cases with corneal decompensation after trauma, and 2 postalkali burn.

In order to show the visual result after the technique, we have designed a special scale table from 1% to 100% in some aspects similar to the logMAR scale, but the special scale table includes the entire cascade from no light perception up to the 20/20 [Table 1]. Table 2 includes 39 cases that had visual improvement after more than 1 year of follow-up, and Table 3 summarizes 19 cases that did not improve in their visual acuity. We show some examples of good visual results after more than 3 year of follow up Figure 4.

Discussion

The introduction of the new technique of transplanting the entire limbal area and removing the whole cornea,

Table 1: Scale of percentage of visual acuity from no light perception up to 20/20

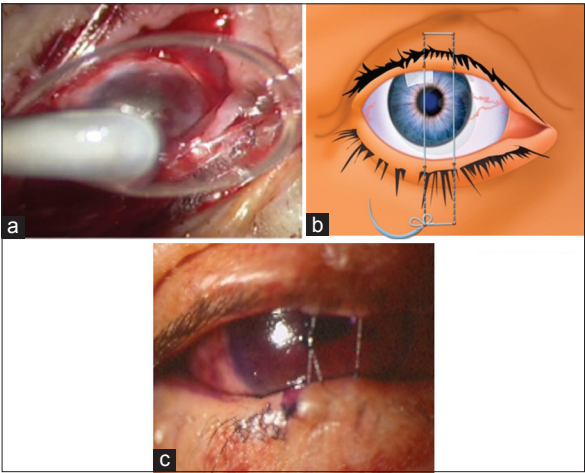
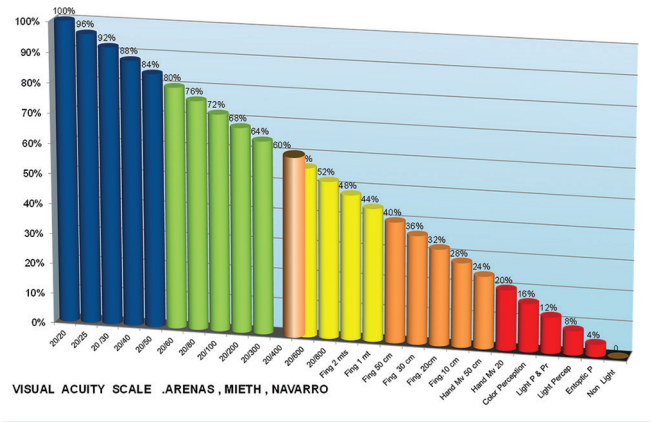


Figure 3: Surgical procedures in lamellar sclerokeratoplasty (continued). (a) A special giant 22-mm hydrophilic soft contact lens is carefully placed over the eye without pushing the donor. (b and c) Partial closure of the eyelid aperture with two "U" 8-0 prolene sutures

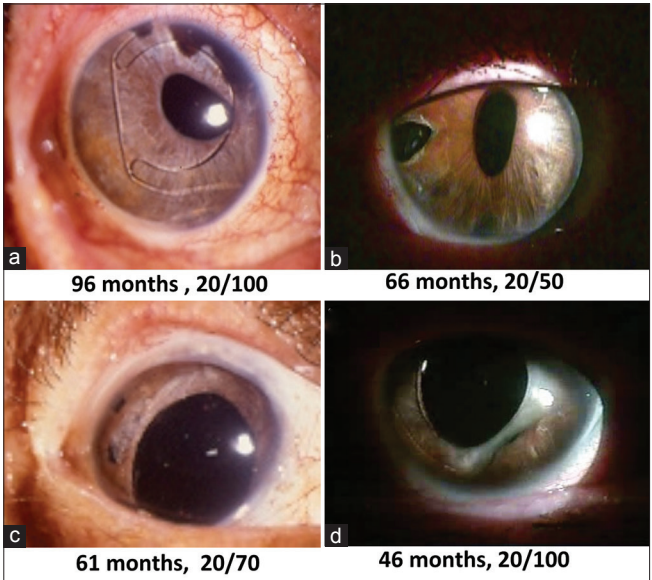


Figure 4: (a-d) Four examples of long-term postoperative follow-up cases with good visual recovery

Table 2: Cases with improvement in visual acuity after >1 year of follow-up

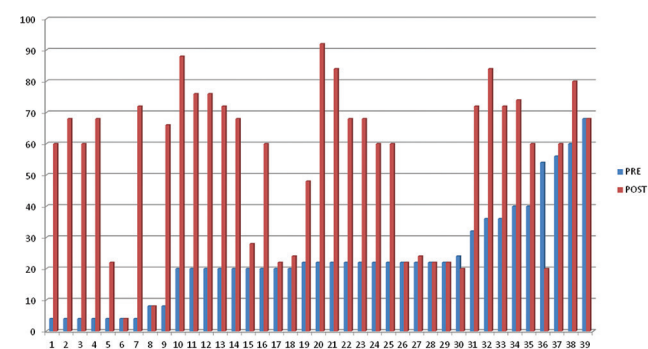
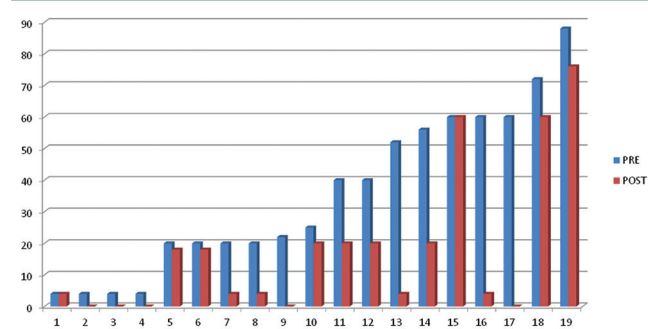


Table 3: Cases that did not show improvement in visual acuity after >1 year of follow-up



without the use of sutures, offers new hope for those eyes not suitable for further standard grafting procedures.^[17] The main goals of a large-diameter lamellar sclerokeratoplasty are to remove the entire anterior-segment pathology, to obtain better optical and cosmetic results by removing all the diseased and inflamed host tissues, and to replace them with a uniform peripheral sclero-corneal tissue.

Visual prognosis in cases that have had previous unsuccessful corneal transplants, other anterior-segment surgeries with complete corneal opacification, and pseudophakic bullous keratopathy with AC-IOL implantation is usually poor.^[18,19] Graft rejection increases when it is necessary to repeat the procedure,^[20,21] and the prognosis almost certainly becomes worse when rejection occurs more than twice.^[22] Some of these eyes, therefore, become candidates for keratoprosthesis, which is also a technique with unpredictable results.^[23,24]

Using a lamellar scleral graft adjacent to the whole cornea facilitates adhesion to the recipient sclera and reconstruction of the anterior-segment anatomy with a clear cornea. The use of lamellar sclera flap together with corneal tissue has also improved the results in transplants with peripheral corneal diseases.^[25,26] Most of these eyes have multiple synechias, vitreous adhesion, iris misplacement, and IOL dislocation. After removing

the corneoscleral button, under a clear and open field, these alterations can be reorganized.^[26] Also, because normal trabecular meshwork structure is introduced with the procedure, some patients pre-operatively have elevated IOP can reduce the need of anti-glaucoma eye drops after this procedure.

The fact that superficial peripheral scleral rim is avascular during the first few weeks of the postoperative period avoids early corneal rejection is frequently observed when large-diameter corneal grafting is performed. Replacing sutures with a fibrin glue sealant is also a factor that diminishes surgical trauma, distortion of the cornea, and postoperative immune reaction. Even in event of graft failure, the procedure can be repeated along the previous incision plane. It is also crucial that the perfect recovery of a smooth ocular surface with the aid of a giant hydrophilic contact lens (Surgilens®) permits normal distribution of the tear film on the new cornea. In successful cases, the ocular surface will look similar to a normal corneo-scleral surface.

Conclusions

The main goals of a large-diameter lamellar sclerokeratoplasty are to remove the entire corneal pathology and to obtain better reconstructive results with less immune reaction. We introduce a technique that replaces sutures with a fibrin glue sealant to diminish surgical trauma and postoperative immune reaction, to recover a smooth ocular surface with normal distribution of the tear film with the use of a giant soft contact lens, and to inject deposit cortisone into the donor cornea to prevent early immunoreaction.^[14] By transplanting the entire limbal area and the whole cornea without the use of sutures, this new technique offers new hope for those eyes not suitable for standard grafting procedures.

Financial support and sponsorship

Nil.

Conflicts of interest

The authors declare that there are no conflicts of interests of this paper.

References

1. Malbran E. Lamellar Keratoplasty in Keratoconus. The Cornea World Congress. Washington: Butterworth Publisher; 1965. p. 507-10.
2. Li C. A clinical analysis of 44 cases of lamellar keratoplasty and sclero-keratoplasty (author's transl). Zhonghua Yan Ke Za Zhi 1979;15:147-9.
3. Hallermann W. Technik und ergebniss ine operative behandlung des keratoglobus. Klin Monatsbl Augenheilkd 1975;166:593-8.
4. Taylor DM, Stern AL. Reconstructive keratoplasty in the management of conditions leading to corneal destruction. Ophthalmology 1980;87:892-904.

5. Girard LJ. Penetrating sclerokeratoplasty. *Cornea* 1982;1:45-51.
6. Ruiz LA, Saldarriaga C. Escleroqueratoplastia penetrante de 16 mm. *Arch Soc Am Oftalmol Optom* 1983;17:19-46.
7. Barraquer C. Escleroqueratoplastia de 16 mm. *Arch Soc Am Oftalmol Optom* 1985;19:25-45.
8. Bialasiewicz AA, Naumann GO. Tectonic keratoplasty in perforated corneal ulcer in Sjögren's syndrome. *Klin Monbl Augenheilkd* 1988;193:554-64.
9. Mendez EA, Daza MT. Sclerokeratoplasty in a case of corneal keloid. *Cornea* 1991;10:183-4.
10. Nikolić LJ. Surgical treatment of destructive diseases of the cornea. *Srp Arh Celok Lek* 1991;119:215-20.
11. Cobo M, Ortiz JR, Safran SG. Sclerokeratoplasty with maintenance of the angle. *Am J Ophthalmol* 1992;113:533-7.
12. Panda A. Lamellolamellar sclerokeratoplasty. Where do we stand today? *Eye (Lond)* 1999;13 (Pt 2):221-5.
13. Arenas E, Barreto G. Use of fibrin Blue in Modified Sclerokeratoplasty. Surgical techniques in anterior and Posterior Keratoplasty. In: John T. Surgical techniques in anterior and Posterior lamellar corneal Surgery. Jaypee Brothers Medical Publishers; 2006. p. 561-8.
14. Kumar S, Panda A. Fibrin glue aided sutureless sclerokeratoplasty with maintenance of chamber angle. *Cornea* 2011;30:588-90.
15. Arenas E. Esclero queratoplastia lamelar. In: Jose B, Campos EA, Belmonte J, editors. *Atlas De Técnicas Complejas En La Cirugía De Segmento Anterior*. Spain: Elsevier; 2013. p. 307-320.
16. Arenas E, Garcia S. A scleral soft contact lens designed for the postoperative management of pterygium surgery. *Eye Contact Lens* 2007;33:9-12.
17. Schraepen P, Koppen C, Tassignon MJ. Visual acuity after penetrating keratoplasty for pseudophakic and aphakic bullous keratopathy. *J Cataract Refract Surg* 2003;29:482-6.
18. Thompson RW Jr., Price MO, Bowers PJ, Price FW Jr. Long-term graft survival after penetrating keratoplasty. *Ophthalmology* 2003;110:1396-402.
19. Rapuano CJ, Cohen EJ, Brady SE, Arentsen JJ, Laibson PR. Indications for and outcomes of repeat penetrating keratoplasty. *Am J Ophthalmol* 1990;109:689-95.
20. Patel NP, Kim T, Rapuano CJ, Cohen EJ, Laibson PR. Indications for and outcomes of repeat penetrating keratoplasty, 1989-1995. *Ophthalmology* 2000;107:719-24.
21. Price FW Jr., Whitson WE, Marks RG. Graft survival in four common groups of patients undergoing penetrating keratoplasty. *Ophthalmology* 1991;98:322-8.
22. Khan B, Dudenhoefer EJ, Dohlman CH. Keratoprosthesis: An update. *Curr Opin Ophthalmol* 2001;12:282-7.
23. Kim MK, Lee JL, Wee WR, Lee JH. Seoul-type keratoprosthesis: Preliminary results of the first 7 human cases. *Arch Ophthalmol* 2002;120:761-6.
24. Jahne MG. 25 years Cardona keratoprosthesis after severe chemical eye burns--long-term outcome of 4 eyes. *Klin Monbl Augenheilkd* 2000;216:191-6.
25. Reinhard T, Sundmacher R. Lamellar horseshoe sclerokeratoplasty and thermoplasty in keratoconus with peripheral ectasia of the cornea. *Klin Monbl Augenheilkd* 1994;205:305-8.
26. Bersudsky V, Blum-Hareuveni T, Rehany U, Rumelt S. The profile of repeated corneal transplantation. *Ophthalmology* 2001;108:461-9.